

CLINICAL CASE REPORT

William W. Curtis, Jr., MD
MidCoast Hospital, Brunswick, ME

Laparoscopic Hiatal Hernia Repair with the Bard* AlloMax* Surgical Graft

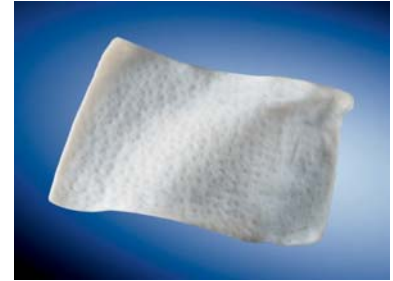Presentation and History

The patient, an 84-year-old male with a history of COPD, HTN, malignant melanoma, bradycardia, and AV pacemaker, presents after losing 30 pounds over the preceding six months with recurrent episodes of epigastric pain associated with nausea, emesis and dysphagia. A Type III Hiatal Hernia with Intra-Thoracic Stomach and organo-axial volvulus was noted on an upper GI study. Pre-operative EGD showed a tortuous esophagus without erosions and mild gastritis. Manometry showed a low-normal amplitude of peristaltic waves and incompetent LES.

Surgical Intervention

After reducing the stomach and hernia intra-abdominally, primary closure of a 6cm defect was performed using 2/0 ETHIBOND* sutures over a 60 French bougie. This resulted in the creation of an approximately 1cm defect in the right crus secondary to the patient's thin, attenuated tissues. A 10x10cm Bard* AlloMax* Surgical Graft was hydrated for several minutes, V-notched anteriorly to accommodate the esophagus, rolled up, and passed through a 10-12mm trocar without difficulty.

After positioning the patch posterior to the esophagus, interrupted sutures of 2/0 ETHIBOND* were used to fix the perimeter of the graft along the medial, lateral and anterior edges. Loose approximation of the patch anteriorly over a 60 French bougie was achieved. The anterior leaflets of the patch were drawn toward one another anteriorly, but not overlapped. A Dor fundoplication was then performed.



Bard* AlloMax* Surgical Graft



A BARD Company

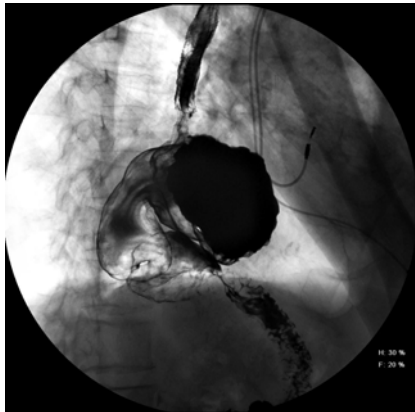Results

Immediate post-operative dysphagia was noted which resolved after 6 weeks. One episode of food bolus impaction occurred at 3 weeks. The bolus was extracted endoscopically with no evidence of recurrent hiatal hernia or esophageal stenosis, and demonstrated correct position of the fundoplication. This was confirmed by a subsequent barium swallow performed 2 days following endoscopy.

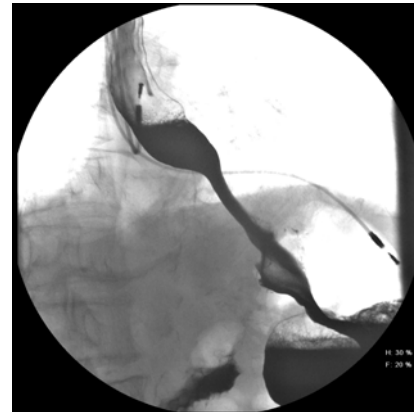
At 3 months, and again at 6 months post-operatively, the patient underwent CT of the thorax for work-up of a pulmonary nodule. The studies demonstrated an intact hiatal hernia repair and fundoplication. At 6 months post-operatively the patient is symptom-free and has returned to normal dietary habits.

Conclusion

The Bard* AlloMax* graft was easily tailored to fit the patient's anatomy and affixed with standard suturing techniques. As of six months, despite being used as a bridge over a small diaphragmatic defect, the repair has remained intact.



Pre-operative Barium Swallow



3 Weeks Post-Operative
Barium Swallow

*Bard and AlloMax are trademarks and/or registered trademarks of C.R. Bard, Inc. or an affiliate. ETHIBOND is a trademark of ETHICON, INC.

The opinions and clinical experiences presented herein are for informational purposes only. The results from this case study may not be predictive for all patients. Individual results may vary depending on a variety of patient specific attributes. The physician has been compensated by Davol Inc. for the time and effort in preparing the clinical case study for Davol's further use and distribution.

Consult product labels and inserts for any indications, contraindications, hazards, warnings, cautions and instructions for use.

© 2008 C.R. Bard, Inc. All rights reserved.
MMCR3



A **BARD** Company

Davol Inc. • Subsidiary of C. R. Bard, Inc.
100 Crossings Boulevard • Warwick, RI 02886
1.800.556.6275 • www.davol.com